L'ONGLE

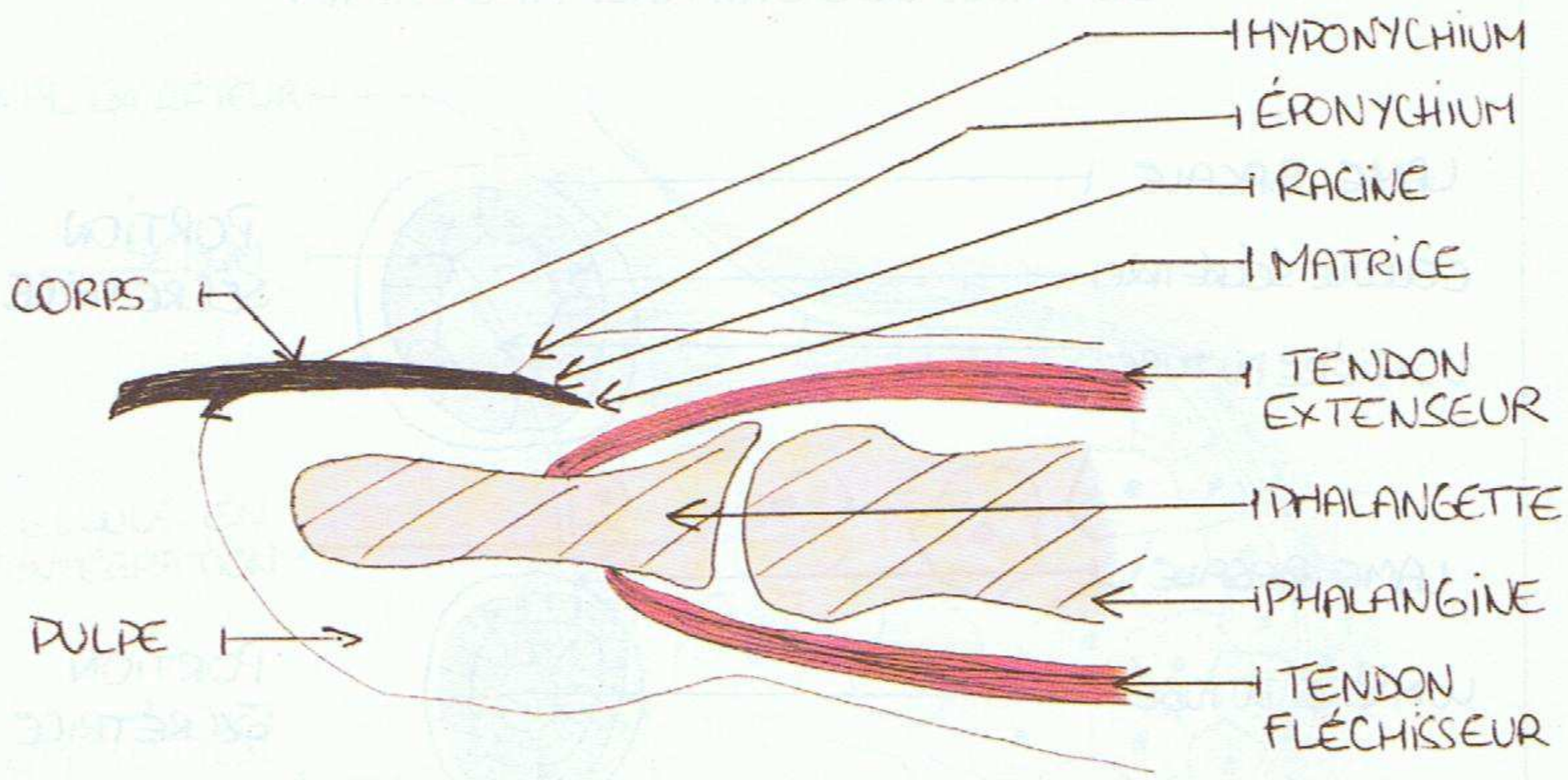

Coupe longitudinale

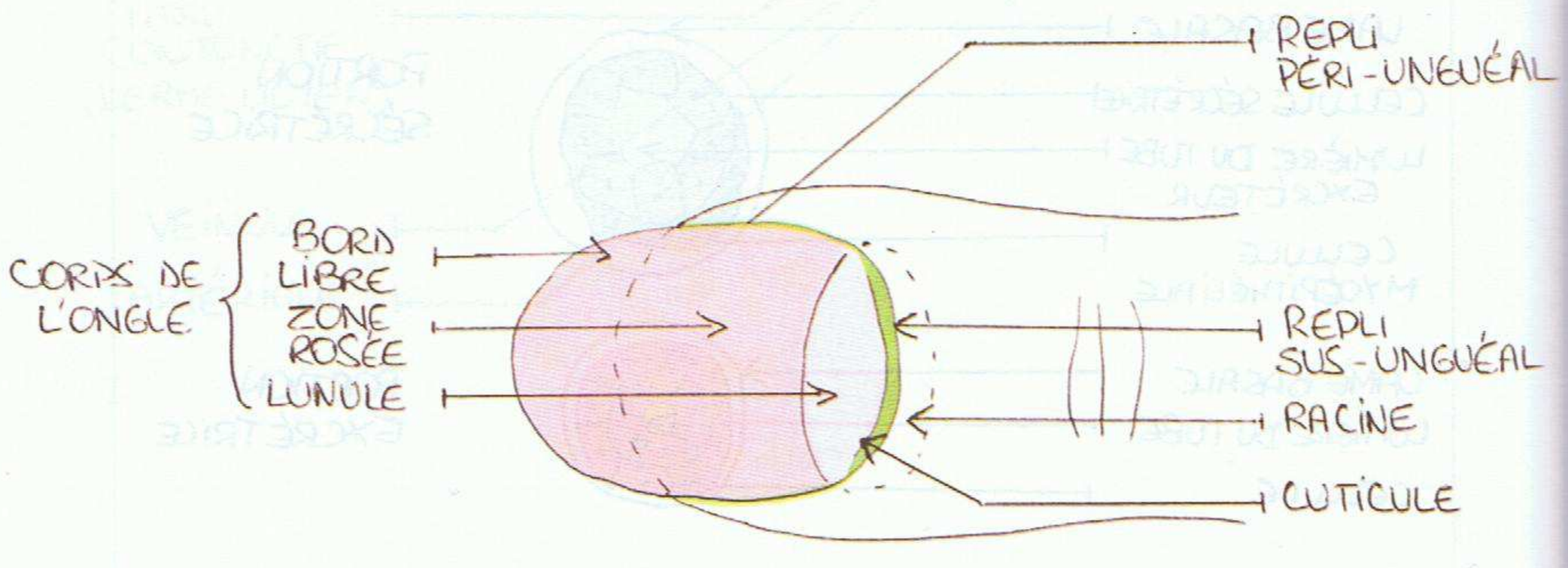

Vue supérieure - Face dorsale du doigt